

# Approach to dizziness in internal medicine: a systematic review

## Revisão sistemática da abordagem da tontura em clínica médica

Lucas Vilas Bôas Magalhães<sup>1</sup>, Vitor Gabriel Ribeiro Grossi<sup>1</sup>, Renato Miyadahira<sup>1</sup>, Ricardo Rocha Bastos<sup>2</sup>

Received from the Department of Medicine and Nursing of the Federal University of Viçosa.

### ABSTRACT

**BACKGROUND AND OBJECTIVES:** One of the most common complaints physicians face is dizziness. Patients with dizziness may have an array of conditions, from benign vertigo to potentially fatal cardiac arrhythmias, and including diverse conditions such as Parkinson's disease and hyponatremia. This is a systematic review of the classification of dizziness, aiming at a more efficient and comprehensive clinical management of the condition, prompted from the presentation of an actual clinical case. **METHODS:** A 63-year-old man, with a 1-year-history of dizziness predominantly on walking, was presented. The complaint prompted a search of the Pubmed and Scielo databases, for flow-charts and systematizations of the approach to the condition. **RESULTS:** Some approaches were identified that were useful in primary care, chiefly Drachman's 4-type classification, which minimizes diagnostic biases. The clinical case was then discussed according to the information found, and a sequence of physical examination maneuvers, to be implemented whenever a patient with dizziness is seen, was presented. **CONCLUSION:** Approaching a patient complaining of dizziness and making its differential diagnosis is a huge intellectual challenge to any physician. There are tools that allow for correct classification of the patients, reduce diagnostic biases, discourage incorrect treatments and reduce expenses.

**Keywords:** Dizziness/ diagnosis; Dizziness/classification; Vertigo

### RESUMO

**JUSTIFICATIVA E OBJETIVOS:** Uma das queixas mais prevalentes e que mais confunde médicos é a tontura. Esses pacientes podem ter desde vertigens benignas até arritmias cardíacas potencialmente fatais, passando ainda por condições tão diver-

sas quanto a doença de Parkinson e a hiponatremia. Este estudo tem por objetivo apresentar uma revisão sistemática sobre as classificações das tonturas, de forma a permitir uma abordagem clínica mais eficiente e abrangente, a partir da apresentação de um caso clínico real. **MÉTODOS:** é apresentado um paciente de 63 anos com queixa de tontura há cerca de 1 ano, principalmente para caminhar. A partir do quadro, foi feita revisão sistemática da literatura no Pubmed e Scielo, buscando os fluxogramas e sistematizações disponíveis para a abordagem da tontura. **RESULTADOS:** foram encontradas algumas formas de abordagem da tontura, muito úteis em atenção primária e clínica médica, especialmente a classificação nas 4 categorias de Drachman, a qual minimiza os vieses diagnósticos. Por fim, foi exposto o desfecho e a discussão do caso, juntamente com uma sugestão de sequência de exame físico a ser realizada em todo paciente com tontura. **CONCLUSÃO:** Saber abordar essa queixa e realizar seu diagnóstico diferencial é um grande desafio intelectual ao médico de qualquer especialidade. Há ferramentas disponíveis que permitem enquadrar o paciente em categorias, evitando vieses diagnósticos, tratamentos incorretos e gastos desnecessários.

**Descritores:** Tontura/ diagnóstico; Tontura/classificação; Vertigem

### INTRODUCTION

The XXI century has witnessed an exponential growth of medical knowledge, with each and every medical topic being the target of daily original articles<sup>(1)</sup>. We now have access to huge sources of evidence-based medicine<sup>(2)</sup>, unheard of until recently. Yet, medical practice is plagued with a widespread inability of general practitioners and specialists alike to diagnose from commonly presenting symptoms. Although interview and physical examination can account for up to 88% of all diagnoses<sup>(3)</sup>, it is all too common to see professionals using these tools precariously (or not at all), and ordering investigations in the hope that a diagnosis may be serendipitously found, with a high risk of false-positive and false-negative results, and consequent suffering and soaring costs. Worse still, drugs may be prescribed or interventions proposed, without a diagnosis (at least a syndromic one) having been reached, and without any evidence of benefit, with the side effects thus resulting adding to the burden sustained by the health systems<sup>(4)</sup>. Honing the basic skills of interview and physical examination is thus a big challenge in graduate education and continuing medical education. The problems outlined could be minimized if evidence-based tools were used in the clinical encounter. The lack of articles on the approach to minor symptoms, an epidemic

1. Universidade Federal de Viçosa, Viçosa, MG, Brazil.

2. Universidade Federal de Juiz de Fora, Juiz de Fora, MG, Brazil.

Date submission: 28/09/2014 – Date accept: 14/10/2014

Conflict of interest: none.

Financial support: none.

#### Corresponding address:

Dr. Lucas Vilas Bôas Magalhães

Avenida PH Rolfs, SN, Centro

CEP 36570-900 – Viçosa, MG, Brazil

Phone: 55(31) 3891-9283 – E-mail: lvbmagalhaes@ufv.br

of this century, is noteworthy<sup>(5)</sup>. Ours is thus a paradoxical situation, in which the deluge of information produced fails to benefit those in most need. This is so because of the translator's fault, the physician, who has the unique role of bridging the gap between the language of an individual afflicted with an illness and the language of science, which can explain that suffering as a disease process. The patients thus carry on crowding the emergency rooms and primary care units with their non-translated (undiagnosed) complaints<sup>(6)</sup>.

In this setting, a very common complaint is dizziness<sup>(7,8)</sup>, impairing the patients' quality of life<sup>(9,10)</sup>, mainly because of the increased risk of depression, falls and fear to fall, and loss of independence<sup>(11,12)</sup>. Because dizziness may puzzle even knowledgeable physicians<sup>(13)</sup>, and many unnecessary and time-consuming might be performed without an adequate clinical hypothesis<sup>(14)</sup>, an approach to this complaint leading to an effective differential is an intellectual challenge to any specialty. Patients complaining of dizziness may have an array of conditions, ranging from benign vertigo to potentially fatal cardiac arrhythmias, and including diverse conditions such as Parkinson's disease and hyponatremia. A clinical tool that can approach this differential with safety is therefore welcome, especially in primary care and internal medicine environments, with obviation of harmful and/or costly management.

We undertook a systematic review of the main available tools to make the differential diagnosis of dizziness, presented a real clinical scenario, and suggested a sequence of physical examination maneuvers, so as to provide a clinical rationale for approaching this common complaint.

## METHODS

A real clinical scenario was presented as a motivational step, showing that the complaint may lead to widely different enoivis. The clinical scenario prompted a systematic literature review, with a well-defined search strategy, using the descriptor "tontura" in the SciELO database (restricted to articles published in Brazil) and "dizziness" crossed with "diagnosis", both in the article titles, in the PubMed database (restricted to articles in English). In order to better clarify some conditions that may lead to dizziness and some of its subtypes, specific descriptors were used: vertigo, presyncope, neurological disorders, psychiatric disorders, guidelines. All the articles found were analyzed, the more pertinent ones being selected according to their potential for immediate clinical applicability and practical relevance, especially those published in the last few years. Some references cited in the articles were analyzed and selected for their interest for the study. The deadline was 28/09/2014. Finally, the flowcharts and approaches were applied to the clinical scenario, with a sequence of physical examination maneuvers to be performed in every patient complaining of dizziness being proposed. Informed consent was given by the patient's carer.

## RESULTS

146 articles were found in the Scielo database, of which only 7 complied with the objectives of the study. PubMed yielded 60

articles, of which 7 were selected. After the bibliographic review of these articles other relevant articles were selected. We noticed a predominant bias of the articles towards vertigo<sup>(15,16)</sup>, with only few publications without this bias<sup>(13,17,18)</sup>. We analyzed the latter in greater detail. See below for application of the information found to the real clinical scenario presented.

*Clinical vignette: A 63-year-old man presented to consultation complaining of dizziness of one-year duration. The dizziness was mainly on walking, with a certain feeling of disequilibrium in the lower limbs. Since he was 18 he has been suffering from generalized tonic-clonic epileptic convulsions, without prodromes and never investigated. He was on carbamazepine, 600mg/day, with good control (almost two years since the last fit), and clonazepam, 2mg/night (prescribed for chronic primary insomnia).*

## Etiology and classification of dizziness

Over 60 diseases or conditions can lead to dizziness: peripheral vestibular disorders, cardiovascular disorders, psychiatric disorders, central or peripheral neurological disorders and side-effects of some drugs being the main examples. In spite of the large number of possible conditions accounting for dizziness, over 90% of the causes can be grouped in 7 main etiological groups. The first tool we learn is then the "Top Seven"<sup>(13)</sup>: peripheral vestibular disorders, hyperventilation, multisensory dizziness, psychiatric disorders (anxiety, panic, agoraphobia, depression), brainstem stroke, neurological disorders (e.g., Parkinsonism and multiple sclerosis), and cardiovascular disorders.

Another approach to dizziness consists of characterizing the 7 dimensions of the symptom, aiming to categorize it according to 4 groups (flowchart 1)<sup>(13)</sup>:

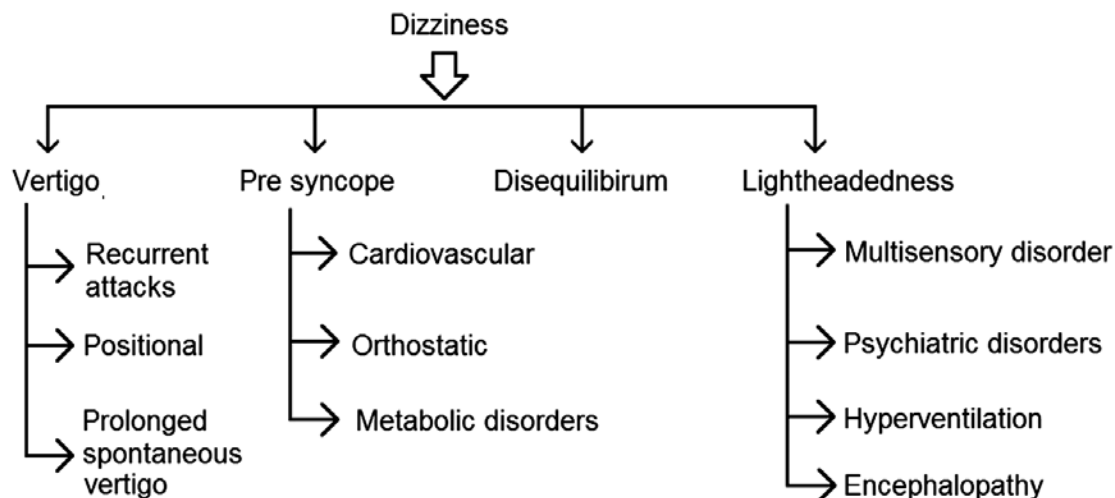
1. Vertigo: rotational sensation of the patient or the environment, along with nausea/vomiting, suggesting peripheral or central vestibular disorders.
2. Presyncope: dim vision and feeling of impending faint, suggesting cardiovascular and metabolic disorders.
3. Disequilibrium (or lower-limb dizziness): in general pointing to neurological impairment.
4. Light-headedness-type dizziness: poorly defined, and generally due to psychiatric disorders.

The fundamentals of each dizziness type are now presented:

### Type 1: Vertigo

Vertigo is not synonymous with dizziness, a commonly held belief. Vertigo implies a feeling of motion of self or the environment in space. When severe, it is typically followed by nausea, vomiting and staggering gait. However, vertigo is a broad term, and includes conditions such as, for instance, cervical vertigo, in which the patient may report symptoms similar to the imbalance possibly related to the position of the cervical structures<sup>(19)</sup>. Awareness of vertigo is situated in the superior temporal gyrus of the cerebral cortex, and involves a mismatch of data sent to the cerebral cortex by the visual, proprioceptive and vestibular systems<sup>(20)</sup>.

From a clinical viewpoint, vertigo may be additionally subdivided into categories<sup>(21,22)</sup>, being the most important 3 types: spontaneous prolonged vertigo, relapsing vertigo attacks, and positional vertigo<sup>(21)</sup>.



**Flowchart 1:** Main categories of dizziness.

- a) Spontaneous prolonged vertigo: the main considerations are acute vestibular neuronitis, stroke (chiefly cerebellar), otomastoiditis, and labyrinthine trauma. Physical examination is typically poor, with the possibility of a positive Romberg test, with a tendency to falling towards the affected side and alteration on the Prussian soldier's march (walking with an excessive elevation of the lower limb, with flexion of the thigh). Horizontal nystagmus, with the rapid component towards the unaffected side, may develop. Cerebellar stroke must be considered in every adult with cardiovascular risk factors who develops spontaneous prolonged vertigo, chiefly if there are associated neurological deficits, such as ataxia and cranial nerve impairment (pointing to involvement of the brainstem). Vertical nystagmus should also alert to the possibility of brainstem disorders: infarction of the pontomesencephalic region leads to upbeat nystagmus. Bilateral commissural lesions between the vestibular nuclei and the cerebellar flocculus lead to downbeat nystagmus. Multidirectional nystagmus that is not suppressed by eye fixation usually points to central vertigo<sup>(23)</sup>. Therefore, horizontal nystagmus generally corresponds to labyrinthine or peripheral vestibular lesions, whereas vertical or multidirectional nystagmus should alert to brainstem lesions. Patients with cerebellar infarction or hemorrhage are generally unable to remain standing unsupported, in spite of keeping their eyes open. It is noteworthy that posterior fossa lesions are always very important, as they can impinge on the brainstem and lead to death. Otomastoiditis must be considered whenever there is evidence of infection or history of labyrinthine trauma.
- b) Relapsing vertigo attacks are relapsing episodes of vertigo of varying duration. Among the main etiologies there are those of neurological origin and those related to ear, nose and throat disorders. Neurological: migraine (not rarely without associated headache), transient ischemic attacks of the posterior circulation (always to be considered in

the presence of cardiovascular risks), and epilepsy (chiefly of the temporal lobe). Ear, nose and throat: Menière's disease<sup>(24)</sup> (vertigo attacks lasting from minutes to hours, with nystagmus, fluctuating hearing impairment and tinnitus, with the possibility of ear pressure/fullness, with normality between the attacks), vestibular neuronitis (may occur with repeated attacks), auto-immune disease of the inner ear (a disputable entity, that should only be considered if there is further evidence of an auto-immune process), and perilymphatic fistula (more frequently following trauma, and leading to important hearing impairment and tinnitus, mainly on exertion). It should be noticed that treatment of relapsing vertigo should not be limited to anti-vertigo drugs, as anticoagulation, steroids, migraine prophylaxis and surgery may be necessary at times.

- c) Positional vertigo: the main cause of vertigo in the general population is Benign Paroxysmal Positional Vertigo (BPPV)<sup>(13,25)</sup> (short latency, short duration, fatigability). BPPV is characterized by a rotational dizziness brought on by head movement and neck hyperextension, with the patient standing or on a recumbent position<sup>(26)</sup>. The dizziness during head motion in BPPV would be provoked by the undue presence of calcium carbonate particles from the breakage of otoliths of the utricular macula<sup>(27)</sup>. BPPV may be diagnosed by the Dix-Hallpike maneuver (patient sitting on the couch, the examiner grasps his head and lowers it fast, to the affected side, with the outer ear facing the floor), and may be cured by Epley's maneuver (repositioning of the otoliths in the semicircular canals). These maneuvers are effective and may be performed by the general practitioner or the patient himself<sup>(28-30)</sup>.

#### **Type 2: presyncope**

Presyncope is a feeling of impending faint or loss of consciousness, generally preceded by dim vision. Other symptoms include autonomic manifestations, such as diaphoresis,

palpitations, pallor and general weakness. Presyncope generally means inadequate supply of blood or nutrients to the brain as a whole<sup>(13)</sup>. Seeing a patient who complains of presyncope we should concentrate on two general groups: cardiovascular disorders and metabolic disorders/anemia. Cardiovascular presyncope is of abrupt onset and may come on regardless of the body position, although it will only happen on standing up if due to orthostatic hypotension. The presence of palpitations, dyspnea and/or chest pain strongly point to a cardiovascular disorder underlying the presyncope. Cardiac auscultation, blood pressure reading (in at least two positions) and pulse palpation are the minimum physical examination here. The clinical encounter should also include an electrocardiogram and a capillary blood glucose measurement, as dizziness/presyncope may indicate changes in glucose metabolism<sup>(31)</sup>.

### Type 3: disequilibrium

Disequilibrium means impaired gait without any abnormal head sensation. The patients sometimes refer to their experience as “dizziness in the feet”<sup>(13)</sup>. True disequilibrium strongly points to neurological disorders, motor or sensitive, central or peripheral. Patients with disequilibrium should undergo a neurological examination including, at least: gait, posture, strength, reflexes, muscle tone, sensitivity, maneuvers for ataxia, and cranial nerves. There are central and peripheral etiologies among the main ones<sup>(32)</sup>: stroke, Parkinsonism<sup>(33)</sup> (Parkinson’s disease, progressive supranuclear palsy, multiple system atrophy, normal pressure hydrocephalus, corticobasal degeneration, among others), myelopathy, multiple sclerosis, motor neuron disease, lumbosacral plexopathy (e.g., radiculoplexopathy or diabetic amyotrophy), polyneuropathy (any disorder involving the peripheral nerves may cause ataxia/weakness with resulting gait disequilibrium), neuromuscular junction disorders (such as myasthenia gravis) and myopathies (several etiologies).

### Type 4: light-headedness

The fourth type of dizziness, as opposed to the other three, is a vague sensation, referred to by the patients with non-specific terms such as light-headedness, heavy-headedness, wooziness, nausea, or confusion. It is a category that encompasses symptoms that cannot be safely included in the other three types. Type 4 dizziness more commonly points to psychiatric disorders (chiefly mood disorders, such as depression, and anxiety disorders, such as generalized anxiety, panic attacks<sup>(34)</sup> and phobias), hyperventilation syndrome, and multisensory dizziness. The latter refers to the coexistence of disorders of various systems (e.g., sight impairment due to cataracts, proprioceptive dysfunction due to diabetic neuropathy, and vestibular impairment due to labyrinthine disorders). Type 4 dizziness is very common in the geriatric population<sup>(13,35)</sup>. It is paramount that these patients be assessed with triage tools for depression, such as sleep, anhedonia, low self-esteem and appetite alteration (SALSA), or even more comprehensive tools for diagnosing psychiatric disorders, such as PRIME-MD<sup>(36)</sup>. In emergency rooms, type 4 dizziness is generally due to panic, the fullest-blown manifestation of anxiety disorders<sup>(34)</sup>. It consists of relapsing panic attacks of sudden onset, without any

identifiable trigger. The attacks develop fully in approximately 10 minutes and resolve abruptly within 1 hour. Agoraphobia may be associated. The panic attack is a well-defined period of intense fear and discomfort, during which there is the sudden appearance of four or more of the following: palpitations, diaphoresis, tremor, suffocation, chest pain, nausea, dizziness, depersonalization, fear of losing control, fear of death, paresthesia, hot feeling, and feeling of stranglement<sup>(37)</sup>.

Some clinical pearls are useful to complement the aforementioned classification<sup>(13)</sup>:

1. A patient with true vertigo has a vestibular impairment. In the absence of a neurological deficit, the cause is a peripheral vestibulopathy. If it happens only and clearly on position changes, it is most likely BPPV. If there is fluctuating hearing impairment and prolonged tinnitus, it is Menière’s syndrome. If there are neurological symptoms or signs, a brainstem disorder (multiple sclerosis, stroke or another) must be considered.
2. Light-headedness episodes exclusively brought on by hyperventilation are obviously due to hyperventilation. This commonly happens when there is anxiety, panic, or agoraphobia, chiefly in women.
3. Type 4, in elders, chiefly those with diabetes, may be due to multisensory impairment - simultaneous disorder of the various sensitive systems. Hesitating gait, neuropathy, sight impairment and vestibular impairment help to identify this pattern.
4. One third of patients complaining of dizziness have an underlying psychiatric disorder. Anxiety and mood disorders are the main etiologies.
5. Stroke may be diagnosed based on the history (sudden onset vertigo) and the presence of physical signs, in patients with cardiovascular risk factors. Subclavian or vertebral bruits increase the likelihood of cerebrovascular disease. A magnetic resonance imaging scan may be necessary for diagnostic confirmation.
6. Cardiovascular or orthostatic disorders cause type 2 dizziness (presyncope) and are clinically diagnosed with significant findings of hypertension or arrhythmia, with proper monitoring, or with electrophysiological stimulation of the heart.
7. A variety of other neurological disorders may cause dizziness: Parkinsonism, frontal lobe lesions, cerebellar lesions, myelopathy.

More information on the clinical vignette:

*Back to the patient, we may consider that his dizziness may be classified as type 1 (maybe due to carbamazepine), type 4 (due to clonazepam)<sup>(18)</sup> or, more likely, type 3. It is clear that further information is necessary.*

*The patient refers to “blocked legs” on walking. There was no pain, paresthesia or dysesthesia. The upper limbs were unaffected. Sight and swallowing were unaffected. In the last year he had had urinary urgency. He was retired after having worked as a farm laborer. The patient’s sister reported that he had found it increasingly difficult to recall recent facts and information. There were no other complaints. This further information highlights*



*type 3 dizziness, and the physical examination must be performed accordingly (neurological maneuvers).*

As can be seen, the clinical encounter begins with the interview, the most powerful tool for diagnosing dizziness<sup>(18)</sup>. As for the main complaint, patients with dizziness may use a wide range of terms to describe their affliction, according to their schooling and previous similar experiences<sup>(27)</sup>. This notwithstanding, each one of the four categories may be reached at with descriptions given by the patients, with the possible exception of light-headedness. If the patient is too vague, it may be useful to present more specific terms to let the patient decide which one best fits his experience. The most relevant elements during history-taking are precipitating factors, chronology (including frequency and duration of symptoms) and associated symptoms<sup>(38)</sup>. Finally, because several drugs may lead to dizziness (anti-hypertensives, anti-epileptics, hypnotics, anxiolytics, among others)<sup>(18)</sup>, it is important that such information is elicited in the interview, although a causal relationship cannot be generally tested immediately. Yet, withdrawal of a certain drug or a substitution when feasible may unveil a drug side-effect as the reason for the dizziness<sup>(39-41)</sup>.

According to the clinical method, the interview is followed by a focused physical examination. We present the “main stem” of the physical examination, with the “branches” that correspond to dizziness. This approach follows a patient-friendly sequence (there is no need to sit, lie, stand several times), saves time and is relatively comprehensive. According to the diagnostic hypotheses (raised during the interview), additional maneuvers (chosen for best performance as refers to sensitivity, specificity and likelihood ratio) are added<sup>(2)</sup>. In this setting, we present a structured physical examination - (SPE) proposed by Bastos et al.,<sup>(42)</sup> and not validated yet, that may guide students and professionals who see patients with dizziness. It is composed of a sequence of 23 maneuvers (the “main stem”) to which are added complementary maneuvers (the “branches”), adequate to the patient’s main complaint.

The structured physical examination (main stem with the dizziness branches)

#### **Patient standing**

1. Weight and height (body mass index (BMI) \*\*\*\*assess gait (absence of arm swing is generally the first indication of the bradykinesia of Parkinsonism) and Romberg (Romberg diagnoses ataxia. Worsening with closed eyes helps to differentiate between sensitive and cerebellar ataxia; worsening points to the former; differential among lesions of the vermix, cerebellar hemisphere or unilateral vestibular is given by the axis of the imbalance. In hysteria, disequilibrium is in the hips and not in the ankles. Positive Romberg is an early indication of posterior column impairment). The pull-test, when positive after the second attempt, may reveal the postural instability of Parkinsonism.

#### **Patient sitting on the couch**

2. Axillary temperature. Obtain capillary blood glucose.
3. Arterial pressure.

4. Eyes\*\*\*\*look for nystagmus. The presence of upbeat nystagmus must be followed by an assessment of the brainstem. A diminished corneal reflex is an early sign of acoustic neuroma.
5. Thyroid and neck lymphnodes.
6. Mouth\*\*\*\*look for facial palsy. Impairment of the VII and VIII cranial pairs suggest a process in the pontocerebellar region.
7. Otoscopy\*\*\*\*Rinnie and Weber tests. Hypoacusia generally precedes vertigo in acoustic neuroma. Cerumem may cause dizziness.
8. Red reflex\*\*\*\*darkening of the red reflex may suggest cataracts as a component of multisensory dizziness.
9. Skin\*\*\*\*pallor may indicate anemia as cause of dizziness. The index-thumb test may reveal digital impedance, and indication of bradikinesia of Parkinsonism. The index-nose test is useful in ataxia.
10. Knee jerk.

#### **Patient supine**

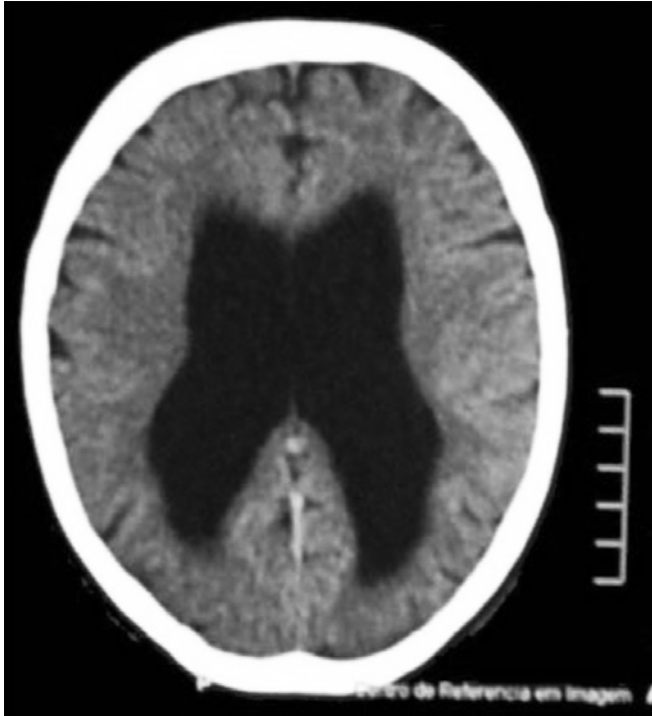
11. Lower limb pulses and edema \*\*\*\*the heel-to-knee test is useful for ataxia. Look for the Babinski sign, proprioception and vibration sensitivity.
12. Arterial pressure.
13. Inspection of the neck.
14. Auscultation of the neck.
15. Cardiac auscultation\*\*\*\*special attention to an irregular rhythm, bradycardia or tachycardia and murmurs. Obtain an electrocardiography (ECG).
16. Abdominal inspection.
17. Abdominal auscultation.
18. Percussion in the Castell point.
19. Liver.
20. Sigmoid.
21. Cecum.
22. General abdominal palpation.

#### **Patient sitting on the couch**

23. Chest auscultation\*\*\*\* Hyperventilation to try and induce the symptoms. Dix-Hallpike. Invite the patient to stand up and measure arterial pressure to assess orthostatic hypotension.

Resolution of the clinical vignette:

*After the interview and the hypothesis if type 3 dizziness (disequilibrium), the physical examination yielded: robot-like shuffling gait, with short steps (apraxic gait, worse on the right), mixed hypertonia of the lower limbs (spasticity and paratonia), brisk reflexes in the lower limbs, bilateral Babinski and ankle clonus. Type 3 dizziness is thus diagnosed, with the combination of gait apraxia, upper motor neuron signs in the lower limbs, hypertonia, urge incontinence and recent subtle memory impairment, pointing to parkinsonism with upper motor neuron features and frontal cortex involvement, mainly compatible with multiple lacunar infarcts or normal pressure hydrocephalus. A skull computer tomography (CT) scan showed communicating hydrocephalus out of proportion with the degree of atrophy (figure 1), and areas of gliosis in the right frontal and left temporal areas (due to trauma sustained during the*



**Figure 1.** Skull CT showing hydrocephalus which is out of proportion to the degree of atrophy.

*epileptic fits?). Complete blood count, and serum glucose, cholesterol, triglycerides, creatinin, urea, liver enzymes, sodium, potassium, B12, folic acid, thyroid stimulating hormones receptors (TSH), and FT4 were within the normal ranges. Serum carbamazepine was within the therapeutic range.*

The patient was admitted for the tap-test. The opening pressure was normal, at 10 cm of water. After 3 hours of drainage of 55ml of cerebrospinal fluid, there was significant improvement of gait speed, number of steps and ability to turn. There was also slight memory improvement. The patient was referred for ventriculoperitoneal shunting and is doing well after the procedure.

## DISCUSSION

Dizziness is a common complaint at every level of care. A systematic approach seeking identification of one of the “top seven” or classification into one of the 4 types (vertigo, presyncope, disequilibrium, light-headedness) is essential to avoid diagnostic traps, specially the early closure cognitive bias (which consists of accepting an initial diagnosis as true, thus closing the door to any alternative reasoning)<sup>(43)</sup>. The case we presented illustrates the diversity of diagnostic possibilities in the setting of dizziness. Managing every patient with dizziness with the prescription of anti-vertigo drugs, “brain circulation enhancers”, and vitamins is a practice to be condemned.

Because it is so common a complaint, how can medical students be trained to approach a patient with dizziness? At which moment and within the content of what subject will

the student learn something effective towards the management of a patient with dizziness? Perhaps in lectures delivered within Clinical Signs and Symptoms, or in the Laboratory of Clinical Skills, the teacher will be able to present the existing algorithms and demonstrate the maneuvers of the structured physical examination. This is a line of investigation we have been pursuing: definition of a frequent condition, edition of an illustrative clinical case<sup>(44)</sup>, review of the best available evidence and development of an adequate physical examination<sup>(2)</sup>, with implementation in the graduate medical course and in continuing medical education programs.

The structured physical examination is a strategy that can and should be used by all physicians, including primary care ones. It is easy to perform and time-saving, allowing for the examination of an undifferentiated outpatient, with evidence-based maneuvers, even in space-limited settings. Tools such as the algorithm and the structured physical examination herein presented make the clinical encounter more meaningful while still feasible, with the bonus of reducing the number of complementary investigations ordered, decreasing dependence on technology of difficult acquisition, reducing costs, and increasing resolution rates.

## REFERENCES

1. Straus SE, Glasziou P, Richardson WS, Haynes RB. Evidence-based medicine: how to practice and teach EBM. 4<sup>th</sup> ed. New York: Churchill- Livingstone; 2010. 312p.
2. Sackett DL. The rational clinical examination. A primer on the precision and accuracy of the clinical examination. JAMA. 1992;267(19):2638-44. Comment in: JAMA. 1992; 267(19):2650-2.
3. Peterson MC, Holbrook JH, Hales D, Smith NL, Staker LV. Contributions of the history, physical examination, and laboratory investigation in making medical diagnoses. West J Med. 1992;156(2):163-5.
4. Bastos RR, Oliveira DS, Pinto EO, Siqueira IO, Ferreira VM. Quem está tonto? O custo-benefício de ferramentas para a tomada de decisões. HU Rev. 2001;27(1):309-11.
5. Benseñor IJ. Minor symptoms: the illness of the 21<sup>st</sup> century. São Paulo Med J, 2001;119(2):46-7.
6. Bastos RR, Maia FS, Pereira FF, Ramos JO, Rios JF, Pernambuco JM, et al. Nem só de falta de recursos padece o SUS (Uma crítica à Tomada de Decisões Clínicas). HU Rev. 1999;25(2):87-91.
7. Kroenke K, Mangelsdorff AD. Common symptoms in ambulatory care: incidence, evaluation, therapy, and outcome. Am J Med. 1989;86(3):262-6. Comment in: Ann Intern Med. 2001;134 (9 Pt 1):783-5.
8. Bittar RS, Oiticica J, Bottino MA, Ganança FF, Dimitrov R. Estudo epidemiológico populacional da prevalência de tontura na cidade de São Paulo. Braz. j. Otorhinolaryngol. 2013;79(6):688-98.
9. Sherer S, Lisboa HR, Pasqualotti A. Dizziness in elderly individuals: otoneurological diagnosis and interference on the quality of life. Rev Soc Bras Fonoaudiol. 2012;17(2):142-50.
10. Rocha Júnior PR, Kozan ES, Moraes JF, Pereira FG, Moreno AB. Reabilitação vestibular na qualidade de vida e sintomatologia de tontura de idosos. Ciênc Saúde Coletiva. 2014;19(8):3365-74.
11. Moraes AS, Soares WJ, Rodrigues RA, Fett WC, Ferriolli E, Perracini MR. Dizziness in community-dwelling older adults: a population-based study. Braz J Otorhinolaryngol. 2011;77(6):691-9.

12. Soares WJ, Moraes SA, Perracini E, Rodrigues M. Fatores associados a quedas e quedas recorrentes em idosos: estudo de base populacional. *Rev Bras Geriatr Gerontol.* 2014;17(1):49-60.
13. Drachman DA. A 69-year-old man with chronic dizziness. *JAMA.* 1998;280:2111-8. Erratum in: *JAMA.* 1999;281(10):899. Comment in: *JAMA.* 1999;282(4):378.
14. Bakhit M, Heidarian A, Ehsani S, Delphi M, Latifi SM. Clinical assessment of dizzy patients: the necessity and role of diagnostic tests. *Glob J Health Sci.* 2014;24;6(3):194-9.
15. Kentala E, Rauch SD. A practical assessment algorithm for diagnosis of dizziness. *Otolaryngol Head Neck Surg.* 2003;128(1):54-9.
16. Zhao JG, Piccirillo JF, Spitznagel EL Jr, Kallogjeri D, Goebel JA. Predictive capability of historical data for diagnosis of dizziness. *Otol Neurotol.* 2011;32(2):284-90.
17. Chan Y. Differential diagnosis of dizziness. *Curr Opin Otolaryngol Head Neck Surg.* 2009;17(3):200-3.
18. Chawla N, Olshaker JS. Diagnosis and management of dizziness and vertigo. *Med Clin N Am.* 2006;90(2):291-304.
19. Yacovino DA, Hain TC. Clinical characteristics of cervicogenic-related dizziness and vertigo. *Semin Neurol.* 2013;33(3):244-55.
20. Froehling DA, Silverstein MD, Mohr DN, Beatty CW. Does this dizzy patient have a serious form of vertigo? *JAMA.* 1994;271(5):385-8. Erratum in: *JAMA.* 1998;279(8):584. Comment in: *JAMA.* 1994;272(17):1323-4; *JAMA.* 1994; 272(17):1324.
21. Baloh RW. Vertigo. *Lancet.* 1998;352(9143):1841-6. Comment in: *Lancet.* 1999; 353(9152):591.
22. Brandt T, Strupp M, Dieterich M. Five keys for diagnosing most vertigo, dizziness, and imbalance syndromes: an expert opinion. *J Neurol.* 2014;261(1):229-31.
23. Karatas M. Central vertigo and dizziness. Epidemiology, differential diagnosis, and common causes. *Neurologist.* 2008;14(6):355-64.
24. American Academy of Otolaryngology Head and Neck Foundation. Committee on Hearing and Equilibrium. Guidelines for the diagnosis and evaluation of therapy in Ménière's disease. *Otolaryngol Head Neck Surg.* 1995;113(3):181-5.
25. Jeon EJ, Park YS, Park SN, Park KH, Kim DH, Nam IC, et al. Clinical significance of orthostatic dizziness in the diagnosis of benign paroxysmal positional vertigo and orthostatic intolerance. *Am J Otolaryngol.* 2013;34(5):471-6.
26. McNaboe E, Kerr A. Why history is the key in the diagnosis of vertigo. *Practitioner.* 2000;244(1612):648-53. Comment in: *Tidsskr Nor Laegeforen.* 2002;122(15):1454.
27. Furman JM, Cass SP. Benign paroxysmal positional vertigo. *N Engl J Med.* 1999;341(21):1590-6.
28. Tanimoto H, Doi K, Katata K, Nibu KI. Self-treatment for benign paroxysmal positional vertigo of the posterior semicircular canal. *Neurology.* 2005;65(8):1299-300.
29. Molnar A, McGee S. Diagnosing and treating dizziness. *Med Clin North Am.* 2014;98(3):583-96.
30. Radtke A, von Brevern M, Tiel-Wilck K, Mainz-Perchalla A, Neuhauser H, Lempert T. Self-treatment of benign paroxysmal positional vertigo: Semont maneuver vs Epley procedure. *Neurology.* 2004;63(1)150-152. Comment in: *Neurology.* 2004; 63(1):8-9.
31. Fonseca AS, Davidsohn SA. Correlação entre tontura e disfunções do metabolismo da glicose. *Rev Bras Otorrinolaringol.* 2006; 72(3):367-9.
32. Garcia FV. Disequilibrium and its management in elderly patients. *Int Tinnitus J.* 2009;15(1):83-90.
33. Basseto JM, Zeigelboim BS, Jurkiewicz AL, Klagenberg KF. Achados otoneurológicos em pacientes com doença de Parkinson. *Rev Bras Otorrinolaringol.* 2008;74(3):350-5.
34. Gurgel JD, Costa KV, Cutini FN, Sarmiento Junior KM, Mezzaselma MA, Cavalcanti HV. Tontura associada a distúrbio do pânico e agorafobia: relato de caso e revisão da literatura. *Rev Bras Otorrinolaringol.* 2007;73(4):569-72.
35. Murlin L, Davies R. Dizziness. *Medicine.* 2008;36(10):535-9.
36. Spitzer RL, Kroenke K, Williams JB. Validation and utility of a self-report version of PRIME-MD: the PHQ Primary Care Study. Primary Care Evaluation of Mental Disorders. Patient Health Questionnaire. *JAMA.* 1999;282(18):1737-44.
37. American Psychiatric Association. Diagnostic and Statistical Manual of Mental Disorders. 4<sup>th</sup> ed. Washington, DC: American Psychiatric Association; 2000.
38. Caplan LR. Dizziness: How do patients describe dizziness and how do emergency physicians use these descriptions for diagnosis? *Mayo Clin Proc.* 2007;(11):1313-5. Comment in: *Mayo Clin Proc.* 2008;83(2):252; author reply 255. *Mayo Clin Proc.* 2008 Feb; 83(2):253-4; author reply 255. *Mayo Clin Proc.* 2008;83(2):254-5; author reply 255.
39. Tusa RJ. Dizziness. *Med Clin N Am.* 2009;93(2):263-71.
40. Tusa RJ, Gore R. Dizziness and vertigo: emergencies and management. *Neurol Clin.* 2012;30(1):61-74.
41. Shoair OA, Nyandegge AN, Slattum PW. Medication-related dizziness in the older adult. *Otolaryngol Clin N Am.* 2011;44(2): 455-71.
42. Bastos RR, Marassi AL, Aguilar KT, Oliveira Junior N. Da enfermagem à sala de aula: como nascem as ferramentas (a propósito da anemia). *Rev Med Minas Gerais.* 2003;13(3):199-207.
43. McDonald CJ. Medical heuristics: the silent adjudicators of clinical practice. *Ann Intern Med.* 1996;124(1 Pt 1):56-62. Comment in: *Ann Intern Med.* 1996;125(1):77-8.
44. Edlow JA. Diagnosing dizziness: we are teaching the wrong paradigm! *Acad Emerg Med.* 2013;20(10):1064-6.