

Hemothorax due to warfarin overdose

Hemotórax secundário a intoxicação varfarínica

Alberto Pereira Ferraz¹, Fabio Freire José²

Recived from Division of Internal Medicine. Escola Paulista de Medicina. Universidade Federal de São Paulo – EPM/UNIFESP – São Paulo, SP, Brasil.

ABSTRACT

The vitamin K antagonists are the most widely used oral anticoagulant. Although bleedings are common side effect, development of hemothorax is rare. Most cases are associated with impairment in pleura or parenchyma structural alteration in the presence of INR values outside therapeutic range. We report the case of a patient with rheumatoid arthritis presenting with massive hemothorax under anticoagulation with warfarin and present an overview of the main aspects related to warfarin overdose. A 58-year-old woman was evaluated due to transvaginal bleeding and dry cough. In her past medical history, rheumatoid arthritis, smoking and deep venous thrombosis was reported. She had clinical signs of anemia and pulmonary auscultation revealed no lung sounds in the lower third of the right hemithorax. The hemoglobin was 7,2g/dL and the international normalized ratio (INR) was greater than 9. The tomographic study showed pleural effusion and pulmonary embolism in the left pulmonary artery with chronic characteristics, but was negative for pulmonary infarct. The patient received crystalloids, vitamin K and transfusions of blood products. Thoracentesis demonstrated presence of hemothorax. After recovery and hospital discharge, an elective pleural biopsy reveals pleural tissue without histological changes and no signs of malignancy. Despite the fact that hemothorax is a rare complication in patients on oral anticoagulants, this occurrence can be life threatening. The evidence of pleural effusion in these patients should always raise the suspicion of hemothorax. Comorbidities that may affect the lung may be predisposing factors for the occurrence of hemothorax, but the roll of pleural and parenchymal diseases of the lung is not fully clarified and investigation of such conditions should be encouraged.

Keywords: Hemothorax/etiology; Warfarin/adverse effects; Vitamin k/antagonist & inhibitors; Anticoagulants/adverse effects; Humans; Case reports

RESUMO

Os antagonistas da vitamina K são os anticoagulantes orais mais utilizados. Embora sangramentos sejam efeitos colaterais comuns, o desenvolvimento de hemotórax é raro. A maioria dos casos está associada ao comprometimento da pleura ou alteração estrutural do parênquima na presença de valores de INR fora da faixa terapêutica. Relatamos o caso de uma paciente com artrite reumatóide e em anticoagulação com varfarina que apresentou-se com hemotórax maciço. Apresentamos também uma visão geral sobre os principais aspectos relacionados à intoxicação varfarínica. Uma mulher de 58 anos de idade foi avaliada devido a sangramento transvaginal e tosse seca. Em seu histórico médico, artrite reumatóide, tabagismo e trombose venosa profunda foram relatados. Ela tinha sinais clínicos de anemia e a ausculta pulmonar revelou ruídos abolidos no terço inferior do hemitórax direito. A hemoglobina era de 7,2g/dL e a relação normatizada internacional (RNI) maior do que 9. O estudo tomográfico mostrou derrame pleural e embolia na artéria pulmonar esquerda com características crônicas, mas foi negativo para infarto pulmonar. O paciente recebeu cristalóides, vitamina K e transfusões de hemocomponentes. A toracocentese demonstrou presença de hemotórax. Após a recuperação e alta hospitalar, uma biópsia pleural eletiva revelou tecido pleural sem alterações histológicas e sem sinais de malignidade. Apesar do fato de que hemotórax é uma complicação rara em pacientes que tomam anticoagulantes orais, esta ocorrência pode ser fatal. A evidência de derrame pleural nesses pacientes deve sempre levantar a suspeita de hemotórax. Co-morbidades que podem afetar o pulmão podem ser fatores predisponentes para a ocorrência de hemotórax, mas o papel de doenças pleurais e parenquimatosas do pulmão não está totalmente esclarecido e a investigação de tais condições deve ser incentivada.

Descritores: Hemotórax/etiologia; Varfarina/efeitos adversos; Vitamina K/antagonistas & inibidores; Anticoagulantes/efeitos adversos; Humanos; Relatos de casos

INTRODUCTION

Non-traumatic hemothorax is a well reported phenomenon that is relatively uncommon in clinical practice. The diagnostic

1. Specialist in Internal Medicine. Escola Paulista de Medicina. Universidade Federal de São Paulo (EPM/UNIFESP), São Paulo, SP, Brazil.

2. Specialist in Internal Medicine. Hospital São Paulo. Escola Paulista de Medicina. Universidade Federal de São Paulo (EPM/UNIFESP), São Paulo, SP, Brazil.

Received on: 15/04/2014 – Accepted on: 29/04/2014

Conflict of interest: none.

Corresponding address:

Alberto Ferraz Pereira

Rua Machado Bittencourt, 300, Apto. 123 – Vila Clementino

CEP 04044-000 – São Paulo, SP, Brazil

Phone: (11) 9 4824 1061 – Email: albertopferraz@gmail.com

© Sociedade Brasileira de Clínica Médica

of hemothorax requires the evidence of a bloody pleural effusion in which the pleural fluid haematocrit is 50% or more of the peripheral blood haematocrit⁽¹⁾. Causes of non-traumatic hemothorax include malignancies, anticoagulant medications, vascular ruptures (aortic dissection, arteriovenous malformations), endometriosis, pulmonary infarctions, adhesions with pneumothorax, hematologic abnormalities such as hemophilia and tuberculosis^(1,2).

CASE REPORT

A 58-year-old black woman, was admitted with a history of intermittent transvaginal bleeding of moderate intensity. She also complained of asthenia and dry cough for 1 month. In her past medical history, rheumatoid arthritis of 5 years duration and one episode of deep venous thrombosis in his left leg 1 year ago was reported. There was no major risk factors such as surgery, diagnosis of malignancy or immobilization related to the episode of deep venous thrombosis. Her medications were 20mg of prednisone, methotrexate 75 milligrams and 10 milligrams of warfarin. She is a heavy smoker and her family history was negative for cancer or thrombosis. Regarding to her international normalized ratio (INR) monitoring, there were no recent medication changes, diet changes or infections, but she did not attend medical visits to check levels of INR.

On physical examination the patient was drowsy but cooperative. Vital signs were as follows: The heart rate was 145bpm, the blood pressure 90x60mmHg, respiratory rate of 26 incursions per minute, pulse oximetry of 86% in room air and 93% while receiving oxygenotherapy of 3 litres per minute. The pulmonary auscultation revealed no lung sounds in the lower third of the right hemithorax. The remainder of her physical examination was unrevealing.

On admission laboratory evaluation, the hemoglobin was 7,2 grams per deciliter, hematocrit was 21,7 percent; the mean cell volume (MCV) was 93,9 femtoliter, mean cell hemoglobin (MCH) 31,2 picogram, mean corpuscular hemoglobin concentration (MCHC) 32,2 gram per deciliter, red blood cell distribution width (RDW) 14,9 percent; the white-cell count was 21800 per cubic millimeter, with 82 percent neutrophils, 12,8 percent lymphocytes, 4,4 percent monocytes. The platelet count was 400.000 per cubic millimeter. The international normalized ratio was greater than 9.

After intravenous hydration with crystalloid solution, administration of vitamin K and transfusions of blood products (2 units of red blood cells and 20mL/Kg of fresh plasma), the patient improved hemodynamic parameters and had complete resolution of transvaginal bleeding.

Chest x-ray showed opacity in all the right hemitorax. The tomographic study for the assessment of pulmonary infarct, a known risk factor for hemothorax in patients on oral anticoagulation, showed the presence of bilateral pleural effusion, extensive in right hemitorax, atelectasis of the lower and medium lobes in the right hemithorax and failure of filling of contrast in the left pulmonary artery with chronic characteristics (Figure 1). Signs of thrombosis with recanalization were found in left leg (Figure 2).

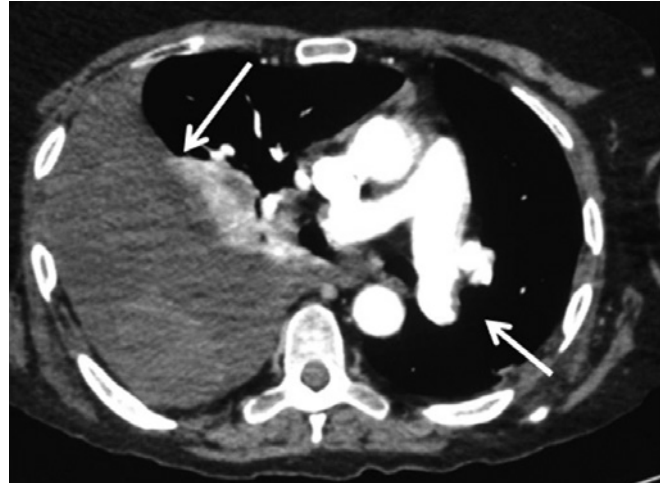


Figure 1. Computed tomography (CT) image showing extensive pleural effusion in right hemithorax and failure of filling of contrast in the left pulmonary artery with chronic characteristics.

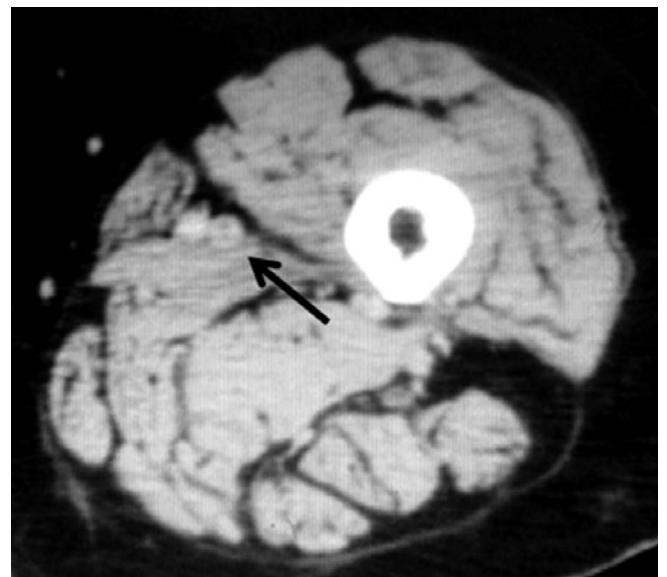


Figure 2. CT with contrast of left lower limb with signs of recanalized thrombosis.

When the INR reached the range of 1,8, the thoracentesis was performed and demonstrated presence of hemothorax. The parameters of the fluid by thoracocentesis were: total cells of 820/mm³, 1 064 000 red blood cells/mm³. The differential count was: Neutrophils 63%, lymphocytes 10%, monocytes 0%, macrophages 22%, mesotheliocytes 5%. Glucose was 130 miligrams per deciliter, total proteins dosage's of 3,7 grams per deciliter. Drainage of 2600 milliliters of hematic fluid was then performed. After recovery and hospital discharge, the patient underwent an elective pleural biopsy, which reveals pleural tissue without histological changes, subpleural alveolar parenchyma with signs of former hemorrhage and no signs of malignancy. At follow-up at 8 months patients is currently doing well.

DISCUSSION

For more than 50 years, oral anticoagulants has promoted effective primary and secondary prevention of arterial and venous thromboembolism. Deep vein thrombosis, pulmonary embolism, atrial fibrillation and prosthetic heart valves are the most common clinical indications for anticoagulation. Despite its unquestionable benefits, as well as most of the drugs in clinical practice, they are not free from side effects. The major complication of anticoagulant therapy is bleeding⁽³⁾. The novel oral anticoagulants as dabigatran and rivaroxaban have lower risk of bleeding and easier clinical management. However, coumarins, the vitamin K antagonists (VKAs), especially warfarin, are still the drug widely use.

Studies vary in the definition and classification of bleeding complications, making it difficult to compare them. Fihn et al., had proposed the following three categories of bleeding: 1- minor (reported, but not requiring additional testing, referrals, or visits - include mild nosebleeds, bruising, mild hemorrhoidal bleeding, and microscopic hematuria); 2- major (requiring treatment, medical evaluation - include overt gastrointestinal bleeding, occult gastrointestinal bleeding if endoscopic studies were done, gross hematuria that prompted cystoscopy or intravenous urography and hemoptysis); 3- life threatening (leading to cardiac arrest, surgical/angiographic intervention, irreversible sequelae - such as myocardial infarction, neurologic deficit consequent to intracerebral hemorrhage-, massive hemothorax, loss of 3 or more units of blood, systolic blood pressure less than 90mmHg, critical anemia)^(4,5).

In 2005 The International Society on Thrombosis and Hemostasis issued a recommendation for definition of major bleeding in studies on antihemostatic products in nonsurgical studies, requiring at least one criterion of three: 1- Fatal bleeding, 2- Symptomatic bleeding in a critical area or organ (such as intracranial, intraspinal, intraocular, retroperitoneal, intrarticular or pericardial) or intramuscular with compartment syndrome, 3- Bleeding causing a fall in hemoglobin level of 2g/dL or more, or leading to transfusion of two or more units of whole blood or red cells⁽⁶⁾. In the case report presented here it was a major bleeding according to both definitions but also a life threatening according to Fihn. Due to the existence of different definitions, the reader should be aware of the definition used in clinical studies.

The major determinants of oral VKA-induced bleeding are the intensity of the anticoagulant effect, patient characteristics, the concomitant use of drugs that interfere with hemostasis, and the length of therapy⁽³⁾. Although the intensity of the anticoagulant effect is one of the most important risk for bleeding, it also can happens in a patient with INR in the therapeutic range. It can be explained by other risk factor such as hypersensitivity to VKA due to a genetic mutation of anticoagulants factors⁽⁷⁾. Among others patient's characteristics age, renal insufficiency, heart failure, cancer, cerebrovascular disease are common factors that increase the risk of bleeding⁽⁴⁾.

An assessment of bleeding risk should be part of the patient assessment before starting anticoagulation. Various bleeding risk scores have been validated to assist the attending physician

in decision-making. The most simple and widely used bleeding risk score is the HAS-BLED, which has been validated for patients with atrial fibrillation. It takes into account the diagnosis of hypertension, of stroke, abnormal renal function, abnormal liver function, bleeding history or predisposition, labile INR, elderly >65, alcohol abuse or use of drugs. A score of ≥ 3 indicates high risk for bleeding, and some caution and regular review of the patient is needed following the initiation of antithrombotic therapy. Specifically for the cases of deep venous thrombosis and pulmonary emboli, we usually did not assess an individual patient's risk of bleeding by clinical prediction rules because its considered that most recommendations would be unlikely to change based on differences in risk of bleeding, although risk factors for this event should be recognized in all patients for more careful follow up.

For all of this cases, none of the available clinical prediction rules exhibit sufficient predictive accuracy or they have trials evaluating the impact of their use on patient outcomes^(8,9).

The patient reported had none of the risk factors previously listed, except the intensity of the anticoagulant effect, and had a HAS-BLED score of 0. She had therefore low risk of bleeding, but the inappropriate ambulatory control of INR should have been considered in the indication and maintenance of anticoagulation treatment.

Overall, hemothorax is very rare in the setting of anticoagulation (3% of all hemorrhagic complications due to warfarin therapy), and most cases occur within the first week of therapy^(1,10). In the case described here, the patient presented a hemothorax one year after initiation of anticoagulation. In the literature review, many of the reported cases of hemothorax related to anticoagulation were associated with an underlying lung disease⁽¹¹⁻¹⁶⁾, although few others cases failure in finding such association⁽¹⁰⁾. In our case, due to the hemothorax match the contralateral hemithorax of the cronic pulmonary embolus, predisposing cause investigation was conducted, but no pleural disease or parenchymal structural alteration that could predisposes the patient to bleeding were identified. Importantly, however, one should consider the sensitivity and accuracy of the biopsy. Although it has better results than blind biopsies, the imaged-guided biopsy cannot safely discard false negatives (sensitivity around 70-76% for malignancy by biopsy guided by ultrasound)^(17,18).

REFERENCES

1. Ali HA, Lippmann M, Mundathaje U, Khaleeq G. Spontaneous hemothorax: a comprehensiv review. *Chest*. 2008;134(5):1056-65.
2. Ganguli A, Walker L, Fitzgerald RJ, Pirmohamed M. Spontaneous hemothorax following anticoagulation with low-molecular-weight heparin. *Ann Pharmacother*. 2009;43(9):1528-31.
3. Schulman S, Beyth RJ, Kearon C, Levine MN; American College of Chest Physicians. Hemorrhagic complications of anticoagulant and thrombolytic treatment: American College of Chest Physicians Evidence-Based Clinical Practice Guidelines (8th Edition). *Chest*. 2008;133(6 Suppl):257S-298S.
4. Fihn SD, Callahan CM, Martin DC, McDonnell MB, Henikoff JG, White RH. The risk for and severity of bleeding complications in

- elderly patients treated with warfarin. The National Consortium of Anticoagulation Clinics. *Ann Intern Med.* 1996;124(11):970-9. Comment in: *Ann Intern Med.* 1997;126(8):660-1.
5. Fihn SD, McDonnell M, Martin D, Henikoff J, Vermes D, Kent D, et al. Risk factors for complications of chronic anticoagulation: a multi-center study. Warfarin Optimized Outpatient Follow-up Study Group. *Ann Intern Med.* 1993;118(7):511-20. Comment in: *Ann Intern Med.* 1993;118(7):511-20. Comment in: *Ann Intern Med.* 1993;119(9):957.
 6. Schulman S, Kearon C; Subcommittee on Control of Anticoagulation of the Scientific and Standardization Committee of the International Society on Thrombosis and Haemostasis. Definition of major bleeding in clinical investigations of antihemostatic medicinal products in non-surgical patients. *J Thromb Haemost.* 2005;3(4):692-4. Comment in: *J Thromb Haemost.* 2012;10(3):496-8.
 7. Gavillet M, Abbal C, Schmidt S, Nötzli J, Lambert JF, Angelillo-Scherrer A. Life-threatening bleeding under vitamin k antagonists in spite of an inr in the therapeutic range. *J Thromb Thrombolysis.* 2011;32(2):232-7.
 8. Loewen P, Dahri K. Risk of bleeding with oral anticoagulants: an updated systematic review and performance analysis of clinical prediction rules. *Ann Hematol.* 2011;90(10):1191-200.
 9. Kearon C, Akl EA, Comerota AJ, Prandoni P, Bounameaux H, Goldhaber SZ, Nelson ME, Wells PS, Gould MK, Dentali F, Crowther M, Kahn SR; American College of Chest Physicians. Antithrombotic therapy for VTE disease: Antithrombotic Therapy and Prevention of Thrombosis, 9th ed: American College of Chest Physicians Evidence-Based Clinical Practice Guidelines. *Chest.* 2012;141(2 Suppl):e419S-94S. Erratum in: *Chest.* 2012; 142(6):1698-1704. Comment in: *Chest.* 2012;142(4):1074-5; author reply 1075-6.
 10. Dogan NO, Pamukçu Günaydin G, Tekin M, Çevik Y. Nontraumatic massive spontaneous hemothorax with concomitant warfarin use. *Case Rep Emerg Med.* 2013;2013:546024.
 11. Ciledag A, Celik G, Koycu G, Gursoy E, Yuksel C. [A rare complication of oral anticoagulant treatment: hemothorax]. *Tuberk Toraks.* 2012;60(1):70-3. Turkish.
 12. Moya Mateo EM, Canora Lebrato J, Madrid Muñoz C, García Largacha M. [Hemomediastinum with bilateral hemothorax after treatment with oral anticoagulation]. *Med Clin (Barc).* 2007;128(1):39. Spanish.
 13. Raghavan R, Ellis AK, Wobeser W, Sutherland KB, O'Donnell DE. Hemopneumothorax in a COPD patient treated with noninvasive positive pressure ventilation: the risk of attendant anticoagulation. *Can Respir J.* 2004; 11(2):159-62.
 14. Guska S. [Hemothorax caused by bleeding inside extralobar pulmonary sequestration in a patient on anticoagulation therapy]. *Med Arh.* 2004;58(1):55-8. Bosnian.
 15. Shahian DM, Venditti FJ Jr. Hemothorax associated with anticoagulation after placement of implantable cardioverter defibrillator: possible similarity to postinfarction Dressler's syndrome. *Pacing Clin Electrophysiol.* 1992;15(9):1233-5.
 16. Simon HB, Dagget MW, DeSanctis RW. Hemothorax as a complication of anticoagulant therapy in the presence of pulmonary infarction. *JAMA.* 1969;208(10):1830-4.
 17. Benamore RE, Scott K, Richards CJ, Entwisle JJ. Image-guided pleural biopsy: diagnostic yield and complication. *Clin Radiol.* 2006;61(8):700-5.
 18. Chang DB, Yang PC, Luth KT, Kuo SH, Yu CJ. Ultrasound-guided pleural biopsy with tru-cut needle. *Chest.* 1991;100(5):1328-33.