

# Pruritus in cholestasis

## Prurido na colestase

Ramiro Anthero de Azevedo<sup>1</sup>, Fernanda Yuri Takamatsu<sup>1</sup>, Mário Kondo<sup>1</sup>, Maria Lúcia Gomes Ferraz<sup>1</sup>, Regina Helena Guedes da Motta Mattar<sup>1</sup>, Silmara da Costa Pereira Cestari<sup>1</sup>, Alcides Augusto Salzedas Netto<sup>1</sup>, Paulo Victor Sgobbi de Souza<sup>1</sup>, Wladimir Bocca Vieira de Rezende Pinto<sup>1</sup>, Flávio Moura Rezende Filho<sup>1</sup>, Acary Souza Bulle Oliveira<sup>1</sup>

Received from Universidade Federal de São Paulo, São Paulo, SP, Brazil.

### ABSTRACT

Pruritus represents one of the main clinical complaints in medical practice, and leads to significant impairment of life quality and some discomfort. Although the knowledge of its main primary and secondary etiologies is well-established in Internal Medicine, especially in Hepatology, its pathophysiological basis and specific therapeutic-directed approaches are still very complex and need a proper systematization for comprehension. This review aims to present the main current themes regarding the main clinical, pathophysiological, therapeutical and management aspects of cholestasis-associated pruritus. **METHODS:** The authors performed a wide review of practical clinical guidelines, review articles and original articles from manuscripts published and indexed in PubMed. **CONCLUSIONS:** Pruritus in cholestasis represents a complex symptom in clinical practice and can be secondary to different pathophysiological mechanisms; its early recognition allows a proper therapeutic approach in most cases.

**Keywords:** Cholestasis/complications; Pruritus/etiology; Skin/innervation; Antipruritics/therapeutic use; Neuralgia/pathophysiology; Review

### RESUMO

O prurido representa uma das principais queixas clínicas na prática médica e origina importante comprometimento da qualidade de vida, além de desconforto. Apesar de suas principais etiologias primárias e secundárias serem de conhecimento bem estabelecido na Clínica Médica, em especial na Hepatologia, suas bases fisiopatológicas e os princípios da terapêutica espe-

cífica direcionada são bastante complexos e necessitam uma sistematização adequada para sua compreensão apropriada. Esta revisão objetiva abordar os principais temas atuais referentes às bases clínicas, fisiopatológicas, terapêuticas e de manejo do prurido relacionados à colestase. Os autores realizaram ampla revisão em diretrizes clínicas práticas, artigos de revisão e publicações originais de artigos publicados e indexados na base PubMed. O prurido na colestase representa um sintoma complexo na prática clínica e pode decorrer de diferentes mecanismos fisiopatológicos secundários. Seu reconhecimento precoce possibilita a abordagem terapêutica apropriada na maioria dos casos.

**Descritores:** Colestase/complicações; Prurido/etiologia; Pele/inervação; Antipruriginosos/uso terapêutico; Neuralgia/fisiopatologia; Revisão

### INTRODUCTION

Pruritus (derived from the latin word *pluritu*) can be defined as an uncomfortable sensation in the skin which generates the need of scratching to produce symptoms relief. It represents one of the most common dermatological complaints in clinical practice. In some cases, pruritus represents a primary dermatological disease sign, however in other cases may represent the presenting symptoms of a complex or severe systemic disease. Particularly in cholestasis, pruritus represents one of the most common general clinical complications, which leads to a complex mixture of unpleasant and debilitating symptoms, and low quality of life for patients and relatives.<sup>(1)</sup>

Although most advances in Neurophysiology, Biochemistry and Molecular Biology have provided a better understanding of the main neural pathways and its neurochemical mediators involved in the pruritus sensation, itching in cholestasis remains in many cases a prominent challenge for clinicians, which justifies the need for providing a broad clinical and basic review in this area.

### CLINICAL FEATURES

Pruritus may arise in the context of acute and chronic cholestasis of intrahepatic or extrahepatic origin, occurring in 20% to 50% of icteric patients. It is a common symptom observed in hepatobiliary disorders, particularly in those related to cholestasis,<sup>(2-4)</sup> which makes its prevalence variable among liver diseases, ranging from 5% in chronic hepatitis C virus

1. Universidade Federal de São Paulo, São Paulo, SP, Brazil.

Received on: 12/07/2017 – Accepted on: 23/11/2016

Financial disclosure: none.

Conflict of interest: none.

#### Corresponding author:

Wladimir Bocca Vieira de Rezende Pinto

Department of Neurology and Neurosurgery, Universidade Federal de São Paulo (UNIFESP) – Estado de Israel Street, 899 – Vila Clementino

Zip code: 04022-002 – São Paulo, SP, Brazil

Phone: +55 (11) 5083-1051 – E-mail: wladimirbrvpinto@gmail.com

© Sociedade Brasileira de Clínica Médica

infection to 70% in primary biliary cirrhosis. Surprisingly, there is no correlation between severity of liver disorders and cholestasis and pruritus intensity.<sup>(5)</sup> In patients with chronic cholestasis, pruritus may represent the presenting symptom, arising years before any other classic clinical and laboratory markers of hepatic dysfunction.<sup>(6)</sup>

Pruritus can be localized or generalized, continuous or intermittent, and can sometimes be represented by a complaint of burning, tingling or pricking sensations on the skin.<sup>(7)</sup> Most cases start generally in the palms of the hands and soles of the feet, progressing to the extensor surface of the upper limbs, face and upper region of the trunk. Its severity can also be graded from mild to severe. In mild presentations, it rarely means some degree of compromise in individual daily activities, which is more common in severe cases that also compromise sleep patterns and causes depression and low quality of life in some cases. In the most severe and refractory cases, it can sometimes lead to suicide attempts.<sup>(1)</sup>

Pruritus can vary day by day and be more intense during the evenings and late afternoon,<sup>(7-11)</sup> and excessive hot and humid weather exacerbates its symptoms,<sup>(1)</sup> as well as dietary changes with meals rich in carbohydrates and the use of tight clothes.<sup>(12)</sup> It is also well-established that acute stress and psycho-emotional situations can trigger or exacerbate its severity.<sup>(1,13)</sup> It is more intense in female patients and exacerbated during menstruation, pregnancy and estrogen use, suggesting a major role of female hormones with the genesis of pruritus.<sup>(14)</sup>

Chronic pruritus and vigorous scratching can lead to skin complications such as abrasions, folliculitis, prurigo nodularis and lichenification.<sup>(1)</sup> It is of difficult relief leading the patient to rub the affected area<sup>(15)</sup> or even leading to the use of sharp tools, like brushes, forks, knives and screwdrivers to promote abrasions to obtain some degree of improvement.<sup>(6)</sup> It generally regresses when liver failure begins<sup>(3,6)</sup> and does not have a linear correlation with alkaline phosphatase serum levels, gamma-glutamyl transferase, bilirubin or serum concentrations of bile salts. Among individuals with pruritus, 11% present with refractory sensation with no relief of symptoms,<sup>(16)</sup> and in cases with cholestasis its severity and refractoriness represent a formal indication of liver transplantation.<sup>(1,17,18)</sup>

Regarding pediatric patients, pruritus may arise early; however, before six months of age, because of motor incoordination, the typical response of scratching is not observed, presenting mainly by irritability, and after seven months of age beginning with scratches in the ears and face and risk of secondary infections of the skin.

## ETIOPATHOGENESIS

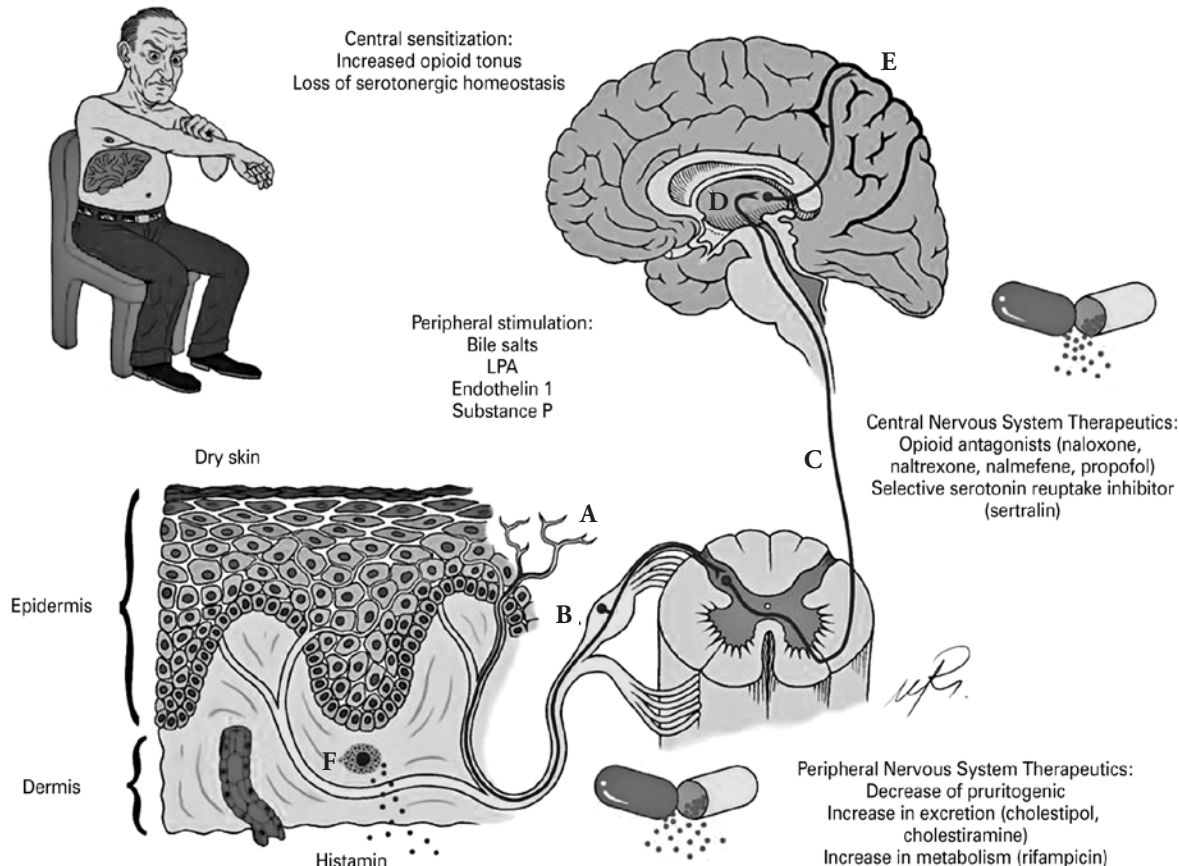
Despite the major advances in the last 15 years in the study of pruritus, its etiopathogenesis in the cholestasis remains poorly understood.<sup>(10,11,19,20)</sup> There are many theories concerning mechanisms and chemical mediators (Figure 1). As it occurs with other sensory modalities, like pain, burning, touch and pressure, pruritus is transmitted from peripheral regions in free nerve terminals in the nociceptors at the dermoepithelial

junction. The polymodal nociceptor is responsive to cold, hot, chemical and mechanical stimuli by means of amyelinic C-fibers, with high excitability threshold and low velocity.

Pruritus sensation is transmitted from the skin by two different neuro pathways by activation of polymodal nociceptors: one by pruritus-selective histamine-activated C-fibers, and another by general C-fibers, non-activated by histamine.<sup>(21)</sup> These fibers project to the second order neuron in the posterior cord in spinal cord and that to a third neuron in the thalamus by means of the spinothalamic tracts.<sup>(22)</sup> From this point on, pruritus sensation is transmitted to different brain regions linked with sensory, behavioral, memory and other modalities.<sup>(13,23)</sup> Synapsis between the first and second order neurons is mediated by glutamate and natriuretic peptide B (Nppb), while between the second and third neurons involves glutamate and gastrin releasing peptide (GRP).<sup>(11,19,23)</sup> However, the most common type of C-fiber is a polymodal nociceptor involved in mechanical and thermic stimuli transmission without permanent activation by histamine and related to pain processing.<sup>(24)</sup> It also establishes synapsis with Bhlbb5 interneuron that after activation inhibits the second neuron from the main pruritus pathway, avoiding its excitability.<sup>(25)</sup> There is also some evidence pointing to the existence of a population of mechanosensitive myelinic A-fibers in the pruritus neurotransmission.<sup>(26)</sup> Thermal, chemical and scratch stimuli can also inhibit the classic pruritus pathway.<sup>(27)</sup> Scratching motor response involves a sequential, alternating and complex activation of sensory and cortical areas,<sup>(28)</sup> many of them also involved in pain processing. Thus, it is widely proved that pain and pruritus result from different patterns of activation of similar cortical and subcortical areas.<sup>(13)</sup> Neuroimaging studies disclose that the periaqueductal gray matter involved in endogenous modulation of pain can also be involved in central inhibition of pruritus by pain stimuli.<sup>(13)</sup> Thus, pruritus central and peripheral pathways are highly susceptible to inhibitory control by polymodal mechanosensitive neurons.<sup>(19)</sup>

The nociceptors are sensitive to various endogenous or exogenous substances, called pruritogens, such as acetylcholine (ACh), calcitonin-gene related peptide (CGRP), corticotropin-releasing hormone (CRH) and pro-opiomelanocortin (POMC), cytokines, endocannabinoids, endothelin (ET), endovanilloids, eicosanoids, histamine, bradykinin, prostaglandin E2 (PGE2), neutrophilins, kallicrein, proteases, leukotriene B4, neurokinin A, neuropeptide/substance P, neurotrophins, opioids, vasoactive intestinal peptide (VIP), and thromboxane A2.<sup>(13,19)</sup> Such pruritogens interact with their respective receptors on nerve terminals such as histamine, active proteinase PRA2, interleukin-31, transient vanilloid potential (TRPV1) and ankyrin transient potential (TRPA1), GRP and Mas-related G protein (Mrgp), which potentiate pain and pruritus transmissions.<sup>(27,29)</sup> In chronic cholestatic or non-cholestatic liver disease, a number of substances accumulate, including nitric oxide, endothelin 1 (ET1), thromboxane A2, leukotrienes, tissue growth factor, prostaglandin, calcitonin-gene related peptide, substance P (SP), vasoactive intestinal peptide, histamine and endocannabinoids.<sup>(30-32)</sup>

After local stimulation, there is local release of SP and CGRP that promote degranulation of histamine by local mastocytes. Despite the levels of histamine being higher in cholestatic



**Figure 1.** Etiopathogenesis and treatment of pruritus in cholestasis. The activation of free nerve terminal endings (A) in the epidermis generates sensitive “inputs” of pruritus, transmitted by C fibers of neurons with its cell bodies and nucleus in the dorsal root ganglion (B). The dorsal root ganglion cells make synapse with intramedullary neurons, whose extensions intersect to the opposite side and form the spinothalamic tract (C), which, in turn, projects to the thalamus (D). From the thalamus, the information is relayed to the sensory cortex (E) and other cortical brain areas related to judgment, emotion, reward and memory. The substances involved in the stimulation of free nerve terminal endings in cholestasis include bile salts, the lysophosphatidic acid (LPA), endothelin 1 and substance P, but dry skin was identified as a significant factor. Mast cells of the dermis (F) release histamine and other inflammatory mediators in response to substances released by the peripheral nervous system, a process that results in positive feedback for the itching sensation. In the central nervous system, the increase in opioid tone and dysregulation of serotonergic transmission contribute to increase pruritus. The therapeutic approach is to reduce the levels of pruritogenic substances in the body, increasing its excretion (cholestyramine, colestipol) or metabolism (rifampicin). Opioid antagonists (naloxone, naltrexone, nalmefene, propofol) and selective serotonin reuptake inhibitors participate in central sensitization.

chronic liver disease patients, other neuromediators also play important roles in pruritus genesis.<sup>(19,33,34)</sup> Moreover, different studies suggest that neither the mastocyte density in skin nor the nerve terminals contribute to cholestatic pruritus.<sup>(35)</sup> Dry skin can directly be a cause of pruritus.<sup>(29)</sup> SP is directly implicated in pain and pruritus signal transduction, but with no correlation of its serum levels to the severity or occurrence of pruritus.<sup>(33)</sup> SP can also stimulate the release of pruritogen compounds of keratinocytes, endothelial cells and immune system humoral compounds.<sup>(27)</sup> ET1 activates mechanosensitive C-fibers causing pain and pruritus.<sup>(36)</sup>

Despite being one of the main contents of bile, bile salts are not directly the cause of pruritus, as its serum, urinary and

skin concentrations do not correlate with pruritus intensity and differentiate them from individuals with or without pruritus, representing only mediators in this process.<sup>(15,34,37)</sup> There are evidences that in cholestasis there is an increase in opioid system participation and this plays a major role as a central mechanism in pruritus. The reason for the modified central neurotransmission in cholestasis is unknown, but it is suspected that methionine, enkephalin and leucine released in high levels after liver dysfunction may play important roles.<sup>(6)</sup> Endogenous opioids seem to participate in the modulation and perception of pruritus, but not directly as a causative factor.<sup>(11,15)</sup> Cholestasis may change serotonin homeostasis and change pruritus change and perception, but not as a direct



causative factor.<sup>(11,15,37)</sup> Pruritus can also be initiated and potentiated by activation of lysophosphatidic acid receptors (LPA),<sup>(11)</sup> with high serum levels of LPA found in patients with cholestatic pruritus.<sup>(15)</sup> Autotaxin (ATX) mediates the production of LPA by the hydrolysis of lisophosphaticholine into LPA. Serum ATX activity in cholestatic patients is elevated in any cause of cholestasis, suggesting a major role of ATX and LPA products in pruritus.<sup>(19,20,33,37,38)</sup> ATX production occurs in many tissues,<sup>(39)</sup> however the main site responsible for cholestatic pruritus is unknown, despite the high suspicion indexes pointing to intestinal origin. Other studies suggest the hypothesis of participation of the bile with the X factor as a stimulating production factor for ATX.<sup>(11)</sup>

Recently, it has been suggested that bile salts, endogenous opioids and LPA act together in pruritus transmission. In this simplified model, bile salts activate skin mastocytes TGR5 receptors and those from terminal nerves inducing pruritus.<sup>(29)</sup> Nerve terminals are also stimulated by LPA that exacerbates pruritus intensity. On the other hand, local mastocytes release local opioids that bring analgesia and enhance pruritus.<sup>(18)</sup> Also in the skin level the interaction of nerve cell and mastocytes, SP, ET1 and neural growth factors released by the nerve terminals stimulate mastocytes that release inflammatory mediators (leukotrienes, prostaglandins and tumor necrosis factor-alpha) and histamine, which release more enhancing factors and promote further mastocyte activation.<sup>(12)</sup>

## TREATMENT

Treatment of cholestasis-related pruritus should take in consideration the pathophysiological aspects and, thus, properly direct therapeutic measures with general approaches and specific directed drugs. The general treatment starts with skin hydration to prevent dryness, which perpetuates the pruritus stimulus when present. Another important approach is to maintain the nails cut and to wear gloves, long sleeves, stockings and collars, mainly during the night, to prevent secondary infections and nodularis pruritus.<sup>(14)</sup>

Drug therapy aims to reduce the amount of pruritogenic substances and mediators in the blood and tissues. The ion exchange resins or chelating substances, such as cholestyramine and colestipol, administered orally, although being hydrophilic, are insoluble in water, by binding to bile acids and other organic components, thus preventing absorption and promoting faecal excretion.

Cholestyramine is administered at a dose of 0.25-0.5g/kg per day (maximum of 16g per day), divided into three to four times a day; it should be taken 20 to 30 minutes before and after meals in patients having an intact gallbladder<sup>8</sup>, adequately mixed and diluted in water or a fruit juice<sup>1</sup>. The recommended dosing for adults is an envelope of the product (4g per envelope) diluted in 100mL of water. Cholestyramine interferes with the bioavailability of various drugs, such as ursodeoxycholic acid, thyroxine, digoxin and oral contraceptives, and fat soluble vitamins. Therefore, it is prudent to wait a 4-hour interval between administration of cholestyramine and other drugs.<sup>(2)</sup>

The main side effect is constipation, but diarrhea, steatorrhea and decreased calcium absorption can also occur, and fat soluble vitamins should be monitored during drug administration. It is difficult to maintain such treatment in childhood because of the low use index.<sup>(7)</sup> Due to its high cost, the mixture of aluminum hydroxide (1 tablespoon) and wheat bran (1 tablespoon) can be alternatively recommended, the effect of which is similar to that of cholestyramine.

The drugs which activate the liver microsomal oxidative system, leading to increase of the metabolism and excretion of endogenous pruritogenic substances are phenobarbital and rifampicin. Phenobarbital seems to have only sedative effects, not directly acting against itching. The normal dose is 2 to 5mg/kg per day. Rifampicin may be effective in relieving itching, and induce laboratory improvement, mainly in gama-glutamyl transferase, particularly in children, when used at a dose of 10mg/kg per day divided into two doses.<sup>(40)</sup> The maximum dose is 600mg. The mechanism responsible for its activation seems to be the activation of cytochrome P450 monooxygenase, which promotes 6-alpha hydroxylation of bile acids and stimulation of their renal excretion.<sup>(41)</sup> However, there might be changes in hepatic transaminases, gama-glutamyl transferase, bilirubin and phosphatase alkaline due to hepatotoxicity and even to other side effects, such as idiosyncratic hypersensitivity reactions (myalgia, fever, headache, arthralgia and gastrointestinal manifestations) and bone marrow depression.

The ursodeoxycholic acid or ursodiol is a hydrophilic bile acid that, when administered for prolonged periods, changes the proportion of endogenous bile salts and decreases the amount of those most harmful to the hepatocyte; moreover, it has choleric and immunomodulatory effects. The dose is 10 to 15mg/kg per day (maximum 500mg/m<sup>2</sup> per day), with diarrhea being the most common side effect on the initiation of treatment.<sup>(3)</sup> For the early treatment of cholestasis pruritus in pediatric patients, besides the general measures, ursodeoxycholic acid is associated, followed by rifampicin.

On the other hand, as it is widely known, itching can be of central origin and in the case of cholestasis the opioidergic and serotonergic systems are hyperstimulated. Therefore, antagonistic drugs that act in such systems have their practical applicability in the treatment of such symptom. Serotonin reuptake inhibitors have been used secondarily for this purpose. Sertraline at a dose of 75 to 100mg per day has been effective for the control of pruritus, and some authors believe it should be recommended as a first-line treatment,<sup>(42)</sup> starting at low doses of 25mg per day and gradually increasing every 4 to 5 days.<sup>(10)</sup>

Opioid receptor antagonists have been used to prevent the central stimulation, being mainly represented by naloxone, naltrexone, nalmefene and propofol. Naloxone should be administered intravenously (IV), intramuscularly (IM), or subcutaneously (SC), and is very useful in the emergency treatment for poisoning by opiates or respiratory depression, and must be prepared daily. Its recommended dose for the itching process is 2mcg/kg per minute in continuous IV infusion, with decrease in pruritus, but not complete remission of symptoms.<sup>(43)</sup> Naltrexone, used for treatment in obese, alcoholics and drug

abuse' patients, may be administered orally, but nausea and opioid withdrawal symptoms (asthenia, irritability, insomnia, hypertension, weight loss, arthralgia and myalgia) often occur. The dose for adults is 50mg per day or 100mg in alternate days, but must begin with 25mg to decrease the risk of side effects. There is no definite dose for pediatric patients in practice, ranging from 1 to 2mg/kg per day in a single dose.<sup>(44)</sup> Nalmefene is chemically similar to naloxone, with the advantages of its oral bioavailability, the most powerful antagonistic action, slower metabolism and longer half-life, with doses of 0.25mcg/kg,<sup>(45,46)</sup> but it is not routinely available in the market. Propofol is a powerful anesthetic agent of short duration that relieves itching caused by morphine and cholestasis due to its hypnotic action and depression of ventral and dorsal spinal cord excitability in doses ranging from 1.5 to 2mg/kg per day.<sup>(47)</sup> Ondansetron, a serotonin antagonistic drug, relieves severe itching when applied intravenously, but remaining for hours, and with pediatric dosing of 0.1mg/kg (up to 4mg), IV, and over 12 years of age with up to 8mg.<sup>(48,49)</sup>

More recent studies suggest that ursodeoxycholic acid should be used in those conditions in which benefit is proven for treatment of the underlying condition, and can be gradually associated with other therapeutic options, including cholestyramine, rifampicin, naltrexone and sertraline. The introduction and general doses of such drugs depend mainly on tolerability and adverse effects profile.<sup>(1,3,4,10,15,34,37)</sup>

Other measures, such as plasmapheresis, phototherapy, antihistamines, anabolic androgens, local or systemic anesthetics (lidocaine), corticosteroids and diets do not represent, in most cases, good cost-benefit ratio drugs compared to most complications and benefits. Phototherapy has been used for over two decades in the treatment of pruritus, with useful results in many dermatological and systemic conditions, such as cholestasis. Its various methods include ultraviolet B (UVB), narrowband UVB (NB), ultraviolet A (UVA) with photochemotherapy with systemic or topically administered psoralen. Currently, it has been shown that NB is safer and can be as effective as UVB and UVA photochemotherapy in the treatment of pruritus, with clinical remission of up to 18 months. The mechanisms proposed for phototherapy include chemical modification of the causative agents and the change in skin sensitivity to such agents.<sup>(50)</sup>

The molecular adsorbent recirculating system (MARS procedure) is an extracorporeal hemofiltration system using a 20% human albumin-enriched dialysate to remove albumin-bound substances in patients with liver failure. These devices are based on the concept that albumin is a complex molecule with a plethora of physiological functions besides the oncotic properties.<sup>(51)</sup> The albumin within the circuit binds protein bound molecules, including bilirubin and bile acids, from the patient.<sup>(51)</sup> These devices are designed to provide additional detoxification functions. Several studies have confirmed that the use of these devices can remove inflammatory molecules, reduce NO, and improve systemic and hepatic hemodynamics in cases of severe hepatic encephalopathy.<sup>(51)</sup> A recent one reports the use of MARS in patients with chronic cholestatic

liver disease or chronic liver graft rejection.<sup>(52)</sup> Two MARS sessions were performed in most patients (either one day apart or in consecutive days). Pruritus dramatically decreased immediately after the procedure (by 72% as assessed by visual analog score) and partially resumed after 30 days but its severity was still significantly lower as compared to baseline (by 51%). This improvement was observed in all but one patient, and was associated with a significant decrease in serum markers of cholestasis, including bile acids. The magnitude of pruritus improvement correlated negatively with baseline serum bile acid and cholesterol levels. No major side effects were observed. Surprisingly, a number of patients remained virtually free of pruritus after a prolonged follow-up (up to 8.6 years). In conclusion, albumin dialysis appears to have a real place in the management of resistant pruritus. However, efficacy is only transient in most cases and, before using this sophisticated invasive treatment modality that has a high cost and potential side effects, it is recommended to use a stepwise medical approach (including optimized administration of the different drugs). Thus, the indication to use invasive procedures should be largely restricted and include only patients with severe intractable pruritus resistant to medical treatment that have a major reduction in quality of life, and be mainly used as an alternative or bridge to liver transplantation.<sup>(35)</sup>

In childhood, in those cases where the liver function is preserved and the possibilities of drug therapy is exhausted, a surgical approach is suggested for the improvement of pruritus. This approach seeks to interrupt the enterohepatic circulation of bile, and to allow it to be eliminated in the feces or through stomas. The techniques used are the internal or external partial biliary diversions. When being used as a treatment for progressive intrahepatic familial cholestasis types 1 and 2, it has been shown to provide good results in non-cirrhotic patients, with improvement of pruritus, normalization of synthetic liver function, lipid metabolism improvement and better growth curve in children.<sup>(53)</sup>

The internal partial biliary shunt can be performed in two patterns. A cholecisto-jejuno-cholo-anastomosis with segmental enterectomy of 5-10cm of jejunum, interposition of the jejunum segment between the gallbladder and the ascending colon, acting as a drainage duct of the bile into the colon. In this technique one plication is performed in the jejunum as an anti-reflux valve to the colonic content of the biliary tract, reducing the incidence of cholangitis.<sup>(54)</sup> A similar technique using the cecal appendix was tested and showed resolution of the pruritus in 75% of patients; 15% needed liver transplantation, and a child died waiting for transplantation. Postoperatively there were high rates of cholangitis as a complication.<sup>(55)</sup> Terminal ileum exclusion can be another surgical approach, with reduction of active absorption of bile salts, and the results are inferior to external diversions with the advantage of absent ostomy and potential reversibility. However, it presents with high index of diarrhea and frequent need to reverse to partial external biliary bypass,<sup>(56)</sup> and frequently with the use of B6 and B12 vitamins orally.

The external partial biliary diversion can also be performed in two techniques. Laparoscopic button cholecystostomy, with

derivation of the gallbladder fundus using similar buttons to this gastrostomy (i.e. MC KeyR) with exteriorization at the right flank. This surgical technique improves pruritus, has low surgical complication rates and high familial acceptance of bile output control.<sup>(57)</sup> Cholecistojunostomy consists of bringing a jejunum segment between the gallbladder and the abdominal wall by marking a permanent stoma for bile drainage.<sup>(58)</sup> This surgical technique has improved up to 75-80% of pruritus, but has been used less frequently nowadays due to its infectious complications, prolapsed stoma, and high volume of biliary excretion leading to dehydration and hyponatremia.<sup>(59)</sup>

In patients with liver function impairment and intense or intermittent pruritus who are awaiting liver transplantation, biliary tract diversion by a temporary endoscopic nasobiliary probe is indicated, providing short-term symptoms relief, but with low acceptance in children.<sup>(60)</sup>

In some cases, even with stable and preserved liver function, being the pruritus refractory to any other clinical and surgical approach and giving rise to severe secondary damage and risks, liver transplantation is indicated.<sup>(2)</sup>

## CONCLUSION

Pruritus represents a major clinical complaint in clinical practice, and different central and peripheral neurologic systems are directly involved in its pathophysiology. Different therapeutic approaches have been proposed in cases of cholestatic pruritus.

## REFERENCES

1. Mela A, Mancuso A, Burroughs AK. Review article: pruritus in cholestasis and other liver diseases. *Aliment Pharmacol Ther.* 2003;17(7):857-70.
2. Heathcote EJ. Management of primary biliary cirrhosis. The American Association for the study of liver diseases practice guidelines. *Hepatology.* 2000;31(4):1005-13.
3. European Association for the study of the liver. EASL Clinical Practice guidelines: Management of liver diseases. *J Hepatol.* 2009;51(2):237-67.
4. Lindor KD, Gershwin ME, Poupon R, Kaplan M, Bergasa NV, Heathcote EJ; American Association for Study of Liver Diseases. Primary biliary cirrhosis. *Hepatology.* 2009;50(1):291-308.
5. Jones DE. Pathogenesis of cholestatic itch: old questions, new answers, and future opportunities. *Hepatology.* 2012;56(4):1194-6.
6. Bergasa NV. The pruritus of cholestasis. *J Hepatol.* 2005;43(6):1078-88.
7. Bergasa NV, Jones EA. The pruritus of cholestasis. Evolving pathogenic concepts suggest new therapeutic options. *Clin Liver Dis.* 1998;2(2):391-405.
8. Glasova H, Buers UJ. Extrahepatic manifestations of cholestasis. *Gastroenterol Hepatol.* 2002;17(9):938-48.
9. Patel T, Ishiuiji Y, Yosipovitch G. Nocturnal itch: Why do we itch at night? *Acta Derm Venerol.* 2007;87(4):295-8.
10. Iman MH, Gossard AA, Sinakos E, Lindor K. Pathogenesis and management of pruritus in cholestatic liver disease. *J Gastroenterol Hepatol.* 2012;27(7):1150-8.
11. Beuers U, Kremer AE, Bolier R, Elferink RP. Pruritus in cholestasis: facts and fiction. *Hepatology.* 2014;60(1):399-407.
12. Metz M, Ständer S. Chronic pruritus – pathogenesis, clinical aspects and treatment. *J Eur Acad Dermatol Venerol.* 2010;24(11):1249-60.
13. Paus R, Schmelz M, Biró T, Steinhoff M. Frontiers in pruritus research: scratching the brain for more effective itch therapy. *J Clin Invest.* 2006;116(5):1174-85.
14. Bergasa NV, Jones EA. The pruritus of cholestasis. *Hepatology.* 1999;29(4):1003-6. Comment in: *Hepatology.* 1999;30(2):586-7.
15. Kremer AE, Elferink RP, Beuers U. Pathophysiology and current management of pruritus in liver disease. *Clin Res Hepatol Gastroenterol.* 2011;35:89-97.
16. Bergasa NV. The itch of liver disease. *Semin Cutan Med Surg.* 2011;30(2):93-8.
17. Kamath BM, Yin W, Miller H, Anand R, Rand EB, Alonso E, Bucuvalas J; Studies of Pediatric Liver Transplantation. Outcomes of liver transplantation for patients with Alagille Syndrome: The studies of pediatric liver transplantation experience. *Liver Transpl.* 2012;18(8):940-8.
18. Dawson PA, Karpen SJ. Bile acids reach out to the spinal cord: new insights to the pathogenesis of itch and analgesia in cholestatic liver disease. *Hepatology.* 2014;59(4):1638-40.
19. Kremer AE, Feramisco J, Reeh PW, Beuers U, Oude Elferink RP. Receptors, cells and circuits involved in pruritus of systemic disorders. *Biochim Biophys Acta.* 2014; 1842(7):869-92.
20. Oude Elferink RP, Bolier R, Beuers UH. Lysophosphatidic acid and signaling in sensory neurons. *Biochim Biophys Acta.* 2015; 1851(1):61-5.
21. Ikoma A, Cevikbas F, Kempkes C, Steinhoff M. Anatomy and Neurophysiology of pruritus. *Semin Cutan Med Surg.* 2011; 30(1):64-70.
22. Davidson S, Zhang X, Khasabov SG, Moser HR, Honda CN, Simone DA, et al. Pruriceptive spinothalamic tract neurons: physiological properties and projection targets in the primate. *J Neurophysiol.* 2012;108(6):1711-23.
23. Dhand A, Aminoff MJ. The neurology of itch. *Brain.* 2014;137(Pt 2): 313-22.
24. Schmelz M, Schmidt R, Weidner C, Hilliges M, Torebjörk HE, Handwerker HO. Chemical response pattern of different classes of C-nociceptors to pruritogens and alogens. *J Neurophysiol.* 2003;89(5):2441-8.
25. Braz J, Solorzano C, Wang X, Basbaum AI. Transmitting pain and itch messages: a contemporary view of the spinal cord circuits that generate gate control. *Neuron.* 2014; 82(3):522-36.
26. Timmers TR, Rothbaum R, Kirti, Silva CY, Bhawan J, Cummins DL, Wolpowitz D. Gastrin-releasing peptide-expressing nerves comprise subsets of human cutaneous A and C fibers that may sense pruritus. *J Invest Dermatol.* 2013;133(11):2645-7.
27. Biró T, Tóth BL, Marincák R, Dobrosi N, Géczy T, Paus R. TRP channels as novel players in the pathogenesis and therapy of itch. *Biochim Biophys Acta.* 2007; 1772(8):1004-21.
28. Yosipovitch G, Ishiuiji Y, Patel TS, Hicks MI, Oshiro Y, Kraft RA, et al. The brain processing of scratching. *J Invest Dermatol.* 2008;128(7):1806-11.
29. Han L, Dong X. Itch mechanisms and circuits. *Annu Rev Biophys.* 2014;43:331-55.
30. Vollmar B, Menger MD. The hepatic microcirculation: mechanistic contributions and therapeutic targets in liver injury and repair. *Physiol Rev.* 2009;89(4):1269-339.
31. García-Pagán JC, Gracia-Sancho J, Bosh J. Functional aspects on the pathophysiology of portal hypertension in cirrhosis. *J Hepatol.* 2012;57(2):458-61.
32. Fernandez M. Molecular pathophysiology of portal hypertension. *Hepatology.* 2015; 61(4):1406-15.
33. Oude Elferink RP, Kremer AE, Martens JJ, Beuers UH. The molecular mechanism of cholestatic pruritus. *Dig Dis.* 2011; 29(1):66-71.



34. Bolier R, Ouder Elferink RP, Beuers U. Advances in pathogenesis and treatment of pruritus. *Clin Liver Dis.* 2013;17(2):319-29.
35. O'Keefe C, Baird AW, Nolan N, McComick PA. Cholestatic pruritus: the role of cutaneous mast cells and nerves. *Aliment Pharmacol Ther.* 2004;19(12):1293-300.
36. Kido-Nakahara M, Buddenkotte J, Kempkes C, Ikoma A, Cevikbas F, Akiyama T, et al. Neural peptidase endothelin-converting enzyme 1 regulates endothelin1-induced pruritus. *J Clin Invest.* 2014;124(6):2683-95.
37. Bunchorntavakul C, Raddy KR. The pruritus in chronic cholestatic liver disease. *Clin Liver Dis.* 2012;16(2):331-46.
38. Kremer AE, van Dijk R, Leckie P, Schaap FG, Kuiper EM, Mettang T, et al. Serum autotoxin is increased in pruritus of cholestasis, but not of other origin, and responds to therapeutic interventions. *Hepatology.* 2012;56(4):1391-400.
39. Nakao M, Sugaya M, Suga H, Kawaguchi M, Morimura S, Kai H, et al. Serum autotoxin levels correlate with pruritus in patient with atopic dermatitis. *J Invest Dermatol.* 2014;134(6):1745-7.
40. Yerushalmi B, Sokol RJ, Narkewicz MR, Smith D, Karrer FM. Use of rifampin for severe pruritus in children with chronic cholestasis. *J Pediatr Gastroenterol Nutr.* 1999;29(4):442-7.
41. Wietholtz H, Marchal HU, Sjøvall J, Mater S. Stimulation of the bile acid 6 $\alpha$ -hydroxylation by rifampin. *J Hepatol.* 1996;24(6):713-8.
42. Mayo MJ, Handen I, Saldana S, Jacobe H, Getashew Y, Rush AJ. Sertraline as a first-line treatment for cholestatic pruritus. *Hepatology.* 2007;45(3):666-74.
43. Bergasa NV, Alling DW, Talbot TL, Swain MG, Yurdaydin C, Turner ML, et al. Effects of naloxone infusions in patients with the pruritus of cholestasis. *Ann Intern Med.* 1995;123(3):161-7.
44. Zellos A, Roy A, Schwarz KB. Use of oral naltrexone for severe pruritus due to cholestatic liver diseases in children. *J Pediatr Gastroenterol Nutr.* 2010;51(6):787-9.
30. Bergasa NV, Alling DW, Talbot TL, Wells MC, Jones EA. Oral nalmefene therapy reduces scratching activity due to the pruritus of cholestasis: a controlled study. *J Am Acad Dermatol.* 1999;41(3 Pt 1):431-4.
46. Bergasa NV, Schmitt JM, Talbot TL, Alling DW, Swain MG, Turner ML, et al. Open-label trial of oral nalmefene therapy for the pruritus of cholestasis. *Hepatology.* 1998;27(3):679-84.
47. Borgeat A, Wilder-Smith OH, Mentha G. Subhypnotic doses of propofol relieve pruritus associated with liver disease. *Gastroenterology.* 1993;104(1):244-7.
48. Raderer M, Müller C, Sheithauer W. Ondansetron for pruritus due to cholestasis. *N Engl J Med.* 1994;330(21):1540.
49. Trioche P, Samuel D, Odièvre M, Labrune P. Ondansetron for pruritus in child with chronic cholestasis. *Eur J Pediatr.* 1996;155(11):990-6.
50. Rivard J, Lim HW. Ultraviolet phototherapy for pruritus. *Dermatol Ther.* 2005;18(4):344-54.
51. Sen S, Williams R. New liver support devices in acute liver failure: a critical evaluation. *Semin Liver Dis.* 2003;23(3):283-94.
52. Pares A, Herrera M, Avilés J, Sanz M, Mas A. Treatment of resistant pruritus from cholestasis with albumin dialysis: combined analysis of patients from three centers. *J Hepatol.* 2010;53(2):307-12.
53. Rebhandl W, Felberbauer FX, Turnbull J, Paya K, Barcik U, et al. Biliary diversion by use of the appendix (cholecystoappendicostomy) in progressive familial intrahepatic cholestasis. *J Ped Gastroenterol Nutr.* 1999;28(2):217-9.
54. Mousavi SA, Karami H. Partial Internal Biliary Diversion in Progressive Familial Intrahepatic Cholestasis: Introduction of a New Approach. *Hepat Mon.* 2014;14(3):13549.
55. Ramachandran P, Shanmugam NP, Sinani SA, Shanmugam V, Srinivas S, Sathiyasekaran M, et al. Outcome of partial internal biliary diversion for intractable pruritus in children with cholestatic liver disease. *Pediatr Surg Int.* 2014;30(10):1045-9.
56. Jankowska I, Czubkowski P, Kaliciński P, Ismail H, Kowalski A, Ryzko J, et al. Ileal exclusion in children with progressive familial intrahepatic cholestasis. *J. Pediatr Gastroenterol Nutr.* 2014;58(1):92-5.
57. Schukfeh N, Gerner P, Paul A, Kathemann S, Metzelder M. Laparoscopic button cholecystostomy for progressive familial intrahepatic cholestasis in two children. *Eur J Pediatr Surg.* 2014;24(5):433-6.
58. Yang H, Porte RJ, Verkade HJ, De Langen ZJ, Hulscher JB. Partial external biliary diversion in children with progressive familial intrahepatic cholestasis and Alagille disease. *J Ped Gastroenterol Nutr.* 2009;49(2):216-21.
59. Halaweish I, Chwals WJ. Long-term outcome after partial external biliary diversion for progressive familial intrahepatic cholestasis. *J Pediatr Surg.* 2010;45(5):934-7.
60. Zellos A, Lykopoulou L, Polydorou A, Tanou K, Jirsa M, Roma E, et al. Nasobiliary drainage in an episode of intrahepatic cholestasis in a child with mild ABCB 11 disease. *J Pediatr Gastroenterol Nutr.* 2012;55(1):88-90.